

V CORSO DI AGGIORNAMENTO AME IN ENDOCRINOLOGIA CLINICA
Agrigento, 20-22 marzo 2014

I NET Intestinali:
° diagnosi e stadiazione
° algoritmo terapeutico

Nadia Cremonini

U.O.S.D. di Endocrinologia
Ospedale Maggiore
Azienda Usl di Bologna

Caso clinico

Lino, anni 73

Buone condizioni generali

Luglio 2012: Ricovero in altra sede per riscontro ecografico di secondarismi epatici (indagine effettuata per cistiti ricorrenti)

Anamnesi recente: da circa 3 anni alvo diarroico (4-5 evacuazioni/die), lievi algie addominali diffuse, episodi fugaci di flushing

PA 140/80 mmHg, Fc 76 b/min R

Anamnesi familiare: madre con DM tipo II

Quale orientamento diagnostico?

S. carcinoide: mediatori e clinica

CLINICAL FEATURES	INCIDENCE, %	CHARACTERISTICS	MEDIATORS
Flushing	90	Foregut tumors: prolonged fit, red-purple, localized to face and trunk	Serotonin, histamine, substance P, prostaglandins
		Midgut tumors: quick fit, pink-red	
Diarrhea	70	Secretory	Serotonin, histamine, VIP, prostaglandins, gastrin
Abdominal pain	40	Long lasting	Obstruction, hepatomegaly, intestinal ischemia, fibrosis
Profuse sweating	15		Serotonin, histamine
Telangiectasia	25	Face	Unknown cause
Heart disease	30 (right)	Valvulopathies (tricuspid and pulmonary), right heart failure, dyspnea	Substance P, serotonin
	10(left)		
Pellagra	5	Dermatitis	Deficit of niacin

Turaga KK et al. CA Cancer J Clin 2011

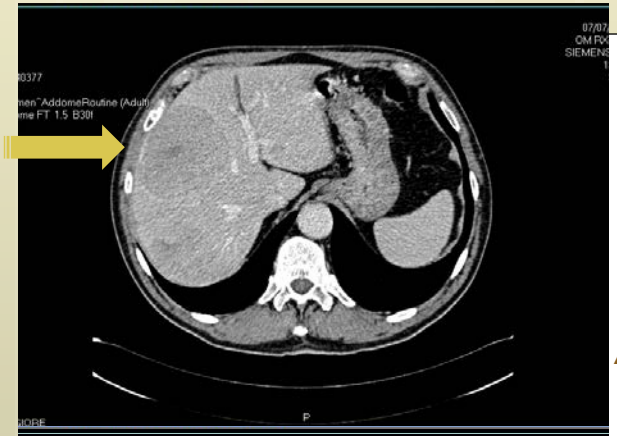

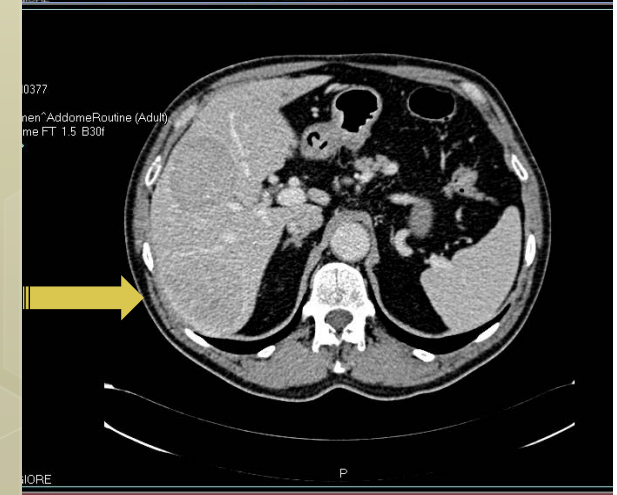

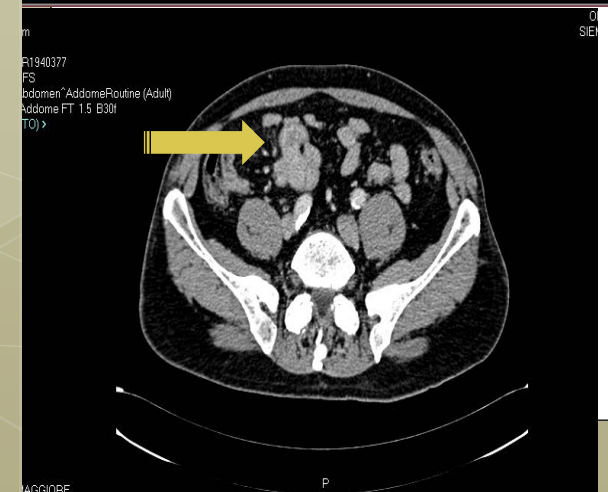

Luglio 2012
TC addome completo mdc

Al parenchima epatico 5 formazioni solide

(VIII segmento di 8,5 cm, passaggio VII-VI 6,5 cm, V due confluenti di 4,5 cm, III segm posteriore 2,5 cm), disomogenea ipervascolarizzazione in fase arteriosa, area centrale di ipovascolarizzazione e modesti fenomeni necrotici intralesionali

Fase tardiva → lesioni ipovascolarizzate rispetto al parenchima epatico

A livello di alcune anse dell'ileo, in sede sotto-ombelicale paramediana dx → conglomerato di anse con intensa impregnazione contrastografica, associato ispessimento del grasso circostante.

Sospetta lesione primitiva intestinale tipo carcinoide, con lesioni sostitutive epatiche

Table 5 Peptide markers specific to the tumour site

Site	Type	Laboratory tests required	Results expected
Gastric	I and II	CgA, gastrin	Raised
	III	CgA, gastrin	Raised CgA, gastrin not raised
Duodenal		CgA, gastrin, PP, urinary 5-HIAA, SOM	Raised CgA in 90% Consider MEN1
Jejunal, ileal and proximal colon		CgA, urinary 5-HIAA, NKA	Raised CgA (>80%), U-5-HIAA (70%) and/or NKA (>80%); see text
Proximal colon		CgA, urinary 5-HIAA, NKA, (PP)	Raised CgA (>80%), U-5-HIAA (70%) and/or NKA (>80%); see text
Appendiceal		CgA, urinary 5-HIAA, NKA, (PP)	None raised unless metastatic Metastatic: markers as ileal
Goblet cell		CgA, urinary 5-HIAA, NKA, (PP)	None raised
Rectal		CgA, CgB, PP, glucagon, HCG-β	Raised CgA (rarely); see text Raised CgB, PP, glucagon and/or HCG-β in some
Pancreatic		CgA	Raised CgA in metastatic tumours only
	Insulinoma	CgA, insulin, blood glucose,	Insulin inappropriate to glucose; see text
		C peptide or pro-insulin	Raised C peptide and pro-insulin
	Gastrinoma	Gastrin	Raised gastrin; see text
	Glucagonoma	Glucagon, enteroglucagon	Raised glucagon
	VIPoma	VIP	Raised VIP
	Somatostatinoma	SOM	Raised SOM
	PPoma	PP	Raised PP
	MEN1	CgA, gastrin, (calcium, PTH), insulin, glucagon, PP	

Ramage JK et al. GUT 2012

Caso clinico

Esami:

Ac 5 OHIAA urine: **88** mg/die (vn 0,7 – 8.2)

Serotonina urine: **55.9** mg/die (vn <4)

Cromogranina : **> 630** U/L (vn 2,0 - 18)

Glucosio: **115** mg/dl (< 100 mg/dl)

HbA1c: **51** mmol/mol (< 42)

- É corretto determinare serotonina urine?
- Per il dosaggio Ac 5-OH IAA ur. e di cromogranina come va preparato il paziente?

Determinazione di 5-OH-IAA urine 24 ore

Table 4 Drugs and foods interfering with 5-HIAA assay	
False negative results	Acetylsalicylic acid Phenothiazines: chlorpromazine, promethazine Imipramine and MAO-inhibitors ACTH Ethanol MethylDOPA and hydrazine derivatives Ketoacids levoDOPA Isoniazid, methenamine, gentisic and homogentisic acid Streptozotocin Heparin
False positive results	Acetaminophen, Naproxen, Phenacetin Caffeine, Nicotine Coumaric acid Diazepam Ephedrine Fluorouracil, Melphalan Phenobarbital Phentolamine, Reserpine, Guaifenesin, Mephenisin Methamphetamine, Phenmetrazine Methocarbamol Mesalamine Foods: bananas, avocados, kiwi, pineapples, peanuts, tomatoes, plums, eggplants, walnuts, pecans, coffee, tea, cocoa/chocolate, vanilla, sweets, and cookies (sugar and marmalade are allowed)

5-OH-IAA urine:

- Può aumentare nelle s. da malassorbimento (i.e celiachia, M. Wipple)
- NET: valori bassi se S. carcinoide assente
- Specificità e sensibilità del 90% in presenza di sindrome da carcinoide

Serotonina plasmatica:

- Metodi poco accurati
- Molti fattori danno falsi positivi
- **Dosaggio non raccomandato nella pratica clinica**

AME Position Statement

Determinazione di Cromogranina A nei GEP-NEN

Patologie associate a incremento di CrA	
Neoplastiche (non GEP-NENs)	Carcinoma mammella Carcinoma prostata Carcinoma ovaio Epatocarcinoma Adenocarcinoma pancreas Carcinoma colon
Non neoplastiche	Insufficienza renale Scompenso cardiaco Patologie endocrine (ipertiroidismo, IPTH) Patologie infiammatorie BPCO Patologie gastro-enteriche: GCA, pancreatite, Patologie intestinali inf. Epatite cronia Cirrosi

CrA:

- Marcatore NON-specifico per NEN
- Può aumentare anche nel soggetto sano dopo il pasto o esercizio fisico
- **Limitato valore diagnostico come esame di prima linea**
- **Sensibilità più elevata nelle forme M1 e/o funzionanti**
- **Sospendere PPI due settimane prima della determinazione**

Biopsia ecoguidata su lesione epatica di maggiori dimensioni, via intercostale (ago Biomol 18 G)

Metastasi epatica da carcinoma neuroen-docrino ben diffe-renziato;

cellule positive per:

sinaptofisina cromogranina

Indice proliferazione Ki67>2%

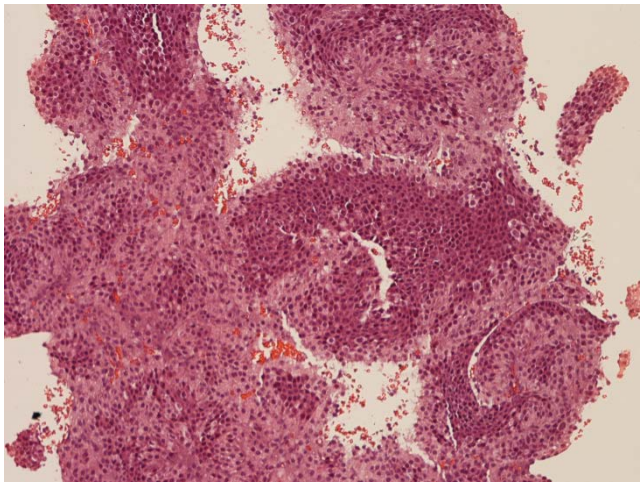

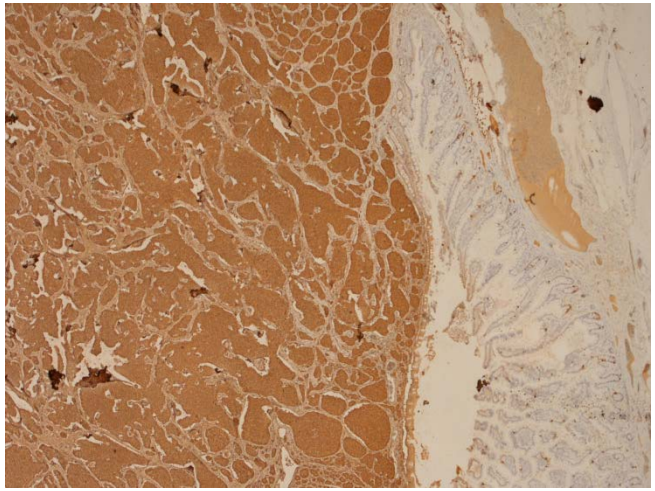

Quesito: doveva essere preparato il paziente?
Se sì: come ?

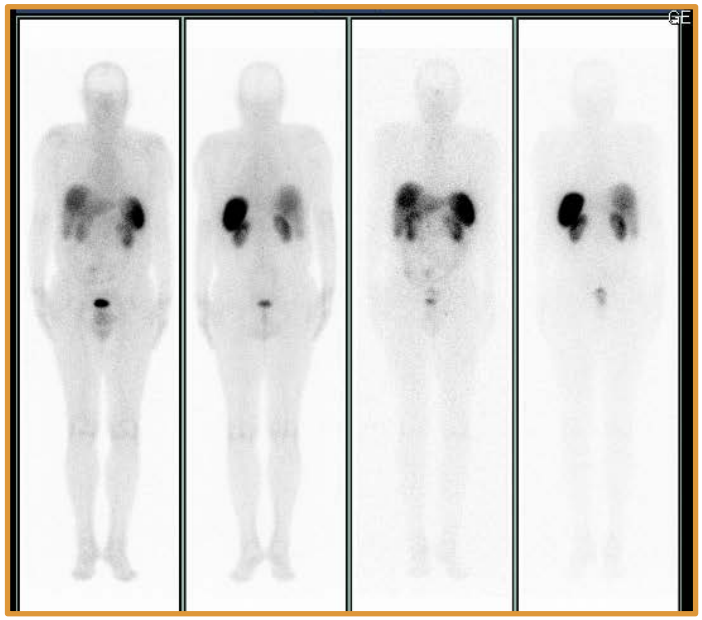

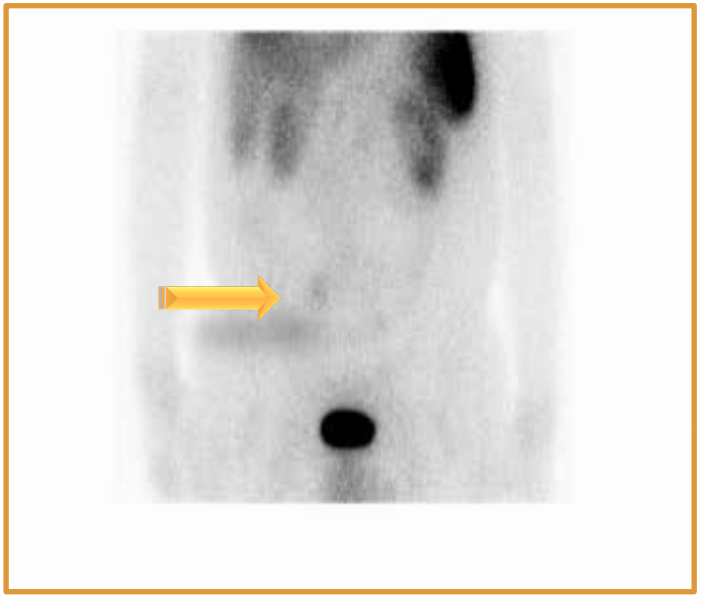

Agosto 2012
111-In-Pentatreotide

- due voluminose aree di intensa fissazione del radiofarmaco in verosimile corrispondenza del VIII e VII-VI segmento epatico e più circoscritta areola al VI segmento epatico, riferibili a note lesioni ripetitive
- areola di iperfissazione del tracciante in verosimile sede ileale dx, corrispondente a reperto segnalato alla TC, sospetta per localizzazione primitiva di malattia
- **Conclusioni**: lesioni esprimenti recettori per la somatostatina ad alta concentrazione a livello epatico ed in sede intestinale ileale

NET digiuno-ileo: presentazione clinica

- Pazienti asintomatici
  - Riscontro incidentale di Metastasi epatiche
  - Screening colonscopia
- Pazienti sintomatici
  - Dolore addominale
  - Diarrea
  - Sindrome carcinoide
  - Rari:
    - Emorragia da ulcerazione lesione
    - decremento ponderale, astenia
    - Nausea e vomito da ostruzione (effetto massa)
    - Ischemia intestinale

Altri accertamenti effettuati per il sig Lino

- Colonscopia sino all'ileo terminale
  - Nell'ileo valutato → piccoli diverticoli
  - Valvola ileo-cecale nella norma
  - Non lesioni a carico di colon e retto
- EGDscopia: non lesioni
- TC torace mdc
  - Non lesioni focali di parenchima e pleura
  - Non linfonodi patologici nel mediastino e agli ili

ITALIAN ASSOCIATION OF CLINICAL ENDOCRINOLOGISTS (AME) POSITION STATEMENT
A STEPWISE APPROACH TO THE DIAGNOSIS OF GASTROENTEROPANCREATIC NEUROENDOCRINE TUMORS IN CLINICAL PRACTICE

Franco Grimaldi[1]*, Nicola Fazio[2]*, Roberto Attanasio[3], Andrea Frasoldati[4], Enrico Papini[5], Francesco Angelini[6], Roberto Baldelli[7], Debora Berretti[8], Sara Bianchetti[6], Giancarlo Bizzarri[9], Marco Caputo[10], Roberto Castello[11], Nadia Cremonini[12], Anna Crescenzi[13], Maria Vittoria Davì[14], Angela Valentina D'Elia[15], Antongiulio Faggiano[16], Stefano Pizzolitto[17], Annibale Versari[18], Michele Zini[4], on behalf of AME oncologic endocrinology group (other members of the group are listed after the text)
* FG and NF contributed equally as first authors

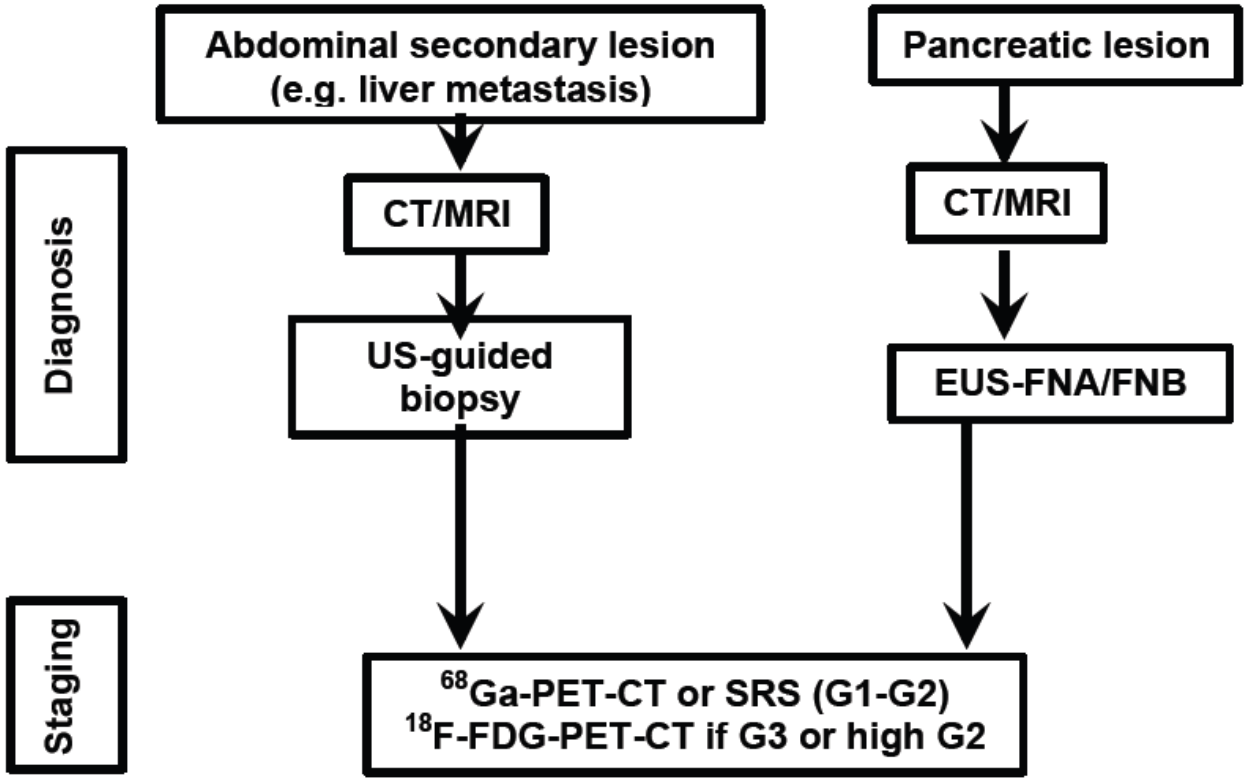

Figure 3
Diagnostic flow-chart for GEP-NET suspected at morphological imaging

ITALIAN ASSOCIATION OF CLINICAL ENDOCRINOLOGISTS (AME) POSITION STATEMENT
A STEPWISE APPROACH TO THE DIAGNOSIS OF GASTROENTEROPANCREATIC NEUROENDOCRINE TUMORS IN CLINICAL PRACTICE

Franco Grimaldi[1]*, Nicola Fazio[2]*, Roberto Attanasio[3], Andrea Frasoldati[4], Enrico Papini[5], Francesco Angelini[6], Roberto Baldelli[7], Debora Berretti[8], Sara Bianchetti[6], Giancarlo Bizzarri[9], Marco Caputo[10], Roberto Castello[11], Nadia Cremonini[12], Anna Crescenzi[13], Maria Vittoria Davì[14], Angela Valentina D'Elia[15], Antongiulio Faggiano[16], Stefano Pizzolitto[17], Annibale Versari[18], Michele Zini[4], on behalf of AME oncologic endocrinology group (other members of the group are listed after the text)
* FG and NF contributed equally as first authors

We recommend chest-abdomen MDCT as the routine morphologic imaging modality for the detection and staging of GEP-NETs.

We recommend MRI when the evaluation of bone and CNS is required. In all the other cases MRI is a second-line imaging study, when MDCT is not conclusive or contraindicated.

We suggest CEUS or MRI for a better characterization of liver involvement.

Quali altri accertamenti avreste effettuato per il Sig Lino?

- TC - Enterografia ?
- Endoscopia a doppio pallone?
- Videocapsula?
- Ecocardiografia?

Come visualizzare i NET ileali?

- Colonscopia
  - se il NET è prolassato attraverso la v. ileo-cecale
  - Se viene incannulata la porzione terminale ileo
- Videocapsula, ma limiti
  - localizzazione precisa del NET di solito non possibile
  - se NET extraluminale, valutazione non accurata
- In casi selezionati -> enteroscopia a doppio pallone:
  - Permette biopsia, accurata localizzazione preoperatoria e la rilevazione di focolai multipli

NEN ileo: possono essere multipli

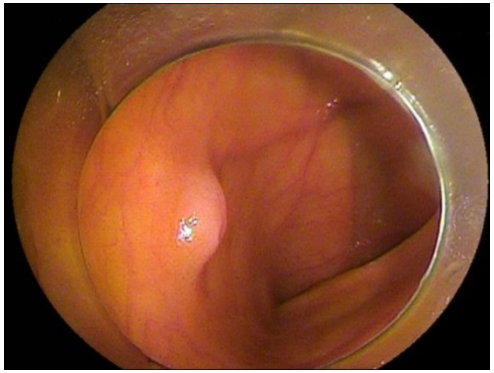

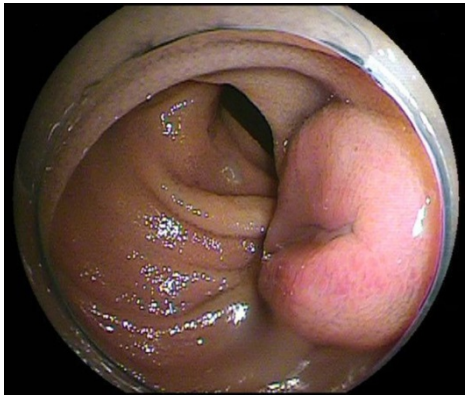

- Enteroscopia a doppio pallone
  - rilevazione di lesione sottomucosa oltre a lesione prevalente ulcerata



Lee SY et al, Med Sci Monit 2012

- Malattia cardiaca da carcinoide (S. Hedinger) presente nel 25-50% dei Pt. con S. da carcinoide
- coinvolge endocardio e valvole del cuore destro:
- Ispessimento di valvole, e accorciamento delle corde tendinee
- Insufficienza v. tricuspide e stenosi v. polmonare
- Dilatazione ventricolo e atrio Dx
- Raro coinvolgimento delle sezioni di sinistra (presente se forame ovale pervio, tumori polmonari)

- Ecocardiografia
- Valutazione cardiologica

ENETS Consensus Guidelines for the Standards of Care in Neuroendocrine Tumors: Pre- and Perioperative Therapy in Patients with Neuroendocrine Tumors

Göran Akerström[a] Massimo Falconi[b] Reza Kianmanesh[c] Philippe Ruszniewski[d] Ursula Plöckinger[e] and all other Mallorca Consensus Conference participants

ino

ctreotide:

ale con
-laterale;
wedge
o sinistro

Minimal Consensus Statement on Perioperative Prophylaxis and Treatment to Prevent Carcinoid Crisis

Patients with carcinoid syndrome should receive octreotide prophylaxis to prevent development of carcinoid crisis during surgery. If patients already receive octreotide or other somatostatin analogues, this medication should be continued while awaiting surgery. Patients who have not received octreotide can be given 100 μg × 3/day subcutaneously for 2 weeks prior to surgery. If more acute operation is needed, octreotide is given for 1–2 days before surgery. Perioperative treatment is recommended with intravenous octreotide, 500 μg in 500 ml saline (50 μg/h), with infusion started before anaesthesia. Remaining symptoms of carcinoid syndrome indicate need of additional intravenous octreotide. In case of a carcinoid crisis reaction with hypotension during anaesthesia, adrenergic drugs should be avoided, and further octreotide should be given.

Neuroendocrinology 2009

Istologia

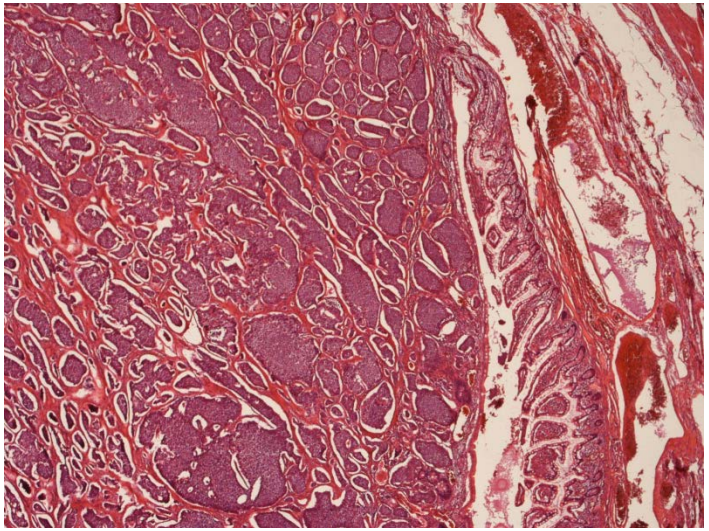

Ultima ansa ileale: nodo biancastro di 3 cm, che infiltra la parete a tutto spessore e si estende al tessuto adiposo periviscerale

→ Tumore neuroendocrino G1 (WHO 2010) dell'ileo, infiltrante a tutto spessore la parete del viscere, esteso ai tessuti adiposi peri ileali e alla superficie sierosa; invasione neoplastica e perineurale; non aree di necrosi

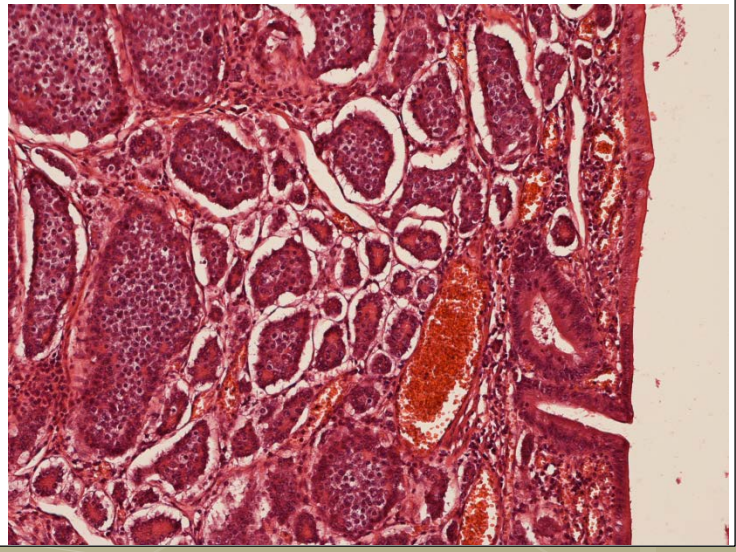

Istologia

- Mitosi <2/10 campi a forte ingrandimento;
- IP Ki67 2%; nella parete ileale noduli neoplastici satelliti peritumorali e a distanza; margini di resezione liberi da neoplasia.
- 3/3 linfonodi perivisceral, 2/2 linf periarteria epatica: N0
- Fegato destro con M1 multiple di NET G1; margine parenchimale indenne

Immunoistochimica

- cc neoplastiche positive per cromogranina e sinaptofisina
- negative per IRI, GLU, gastrina, SMS, serotonina, VIP, PP

Stadiazione pT4,pN0,pM1 sec. UICC/AJCC 2010

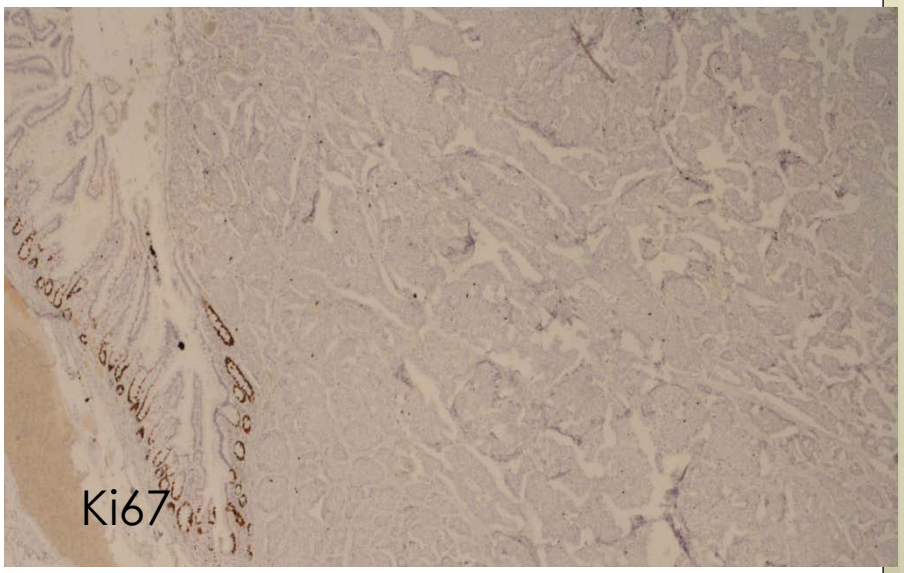

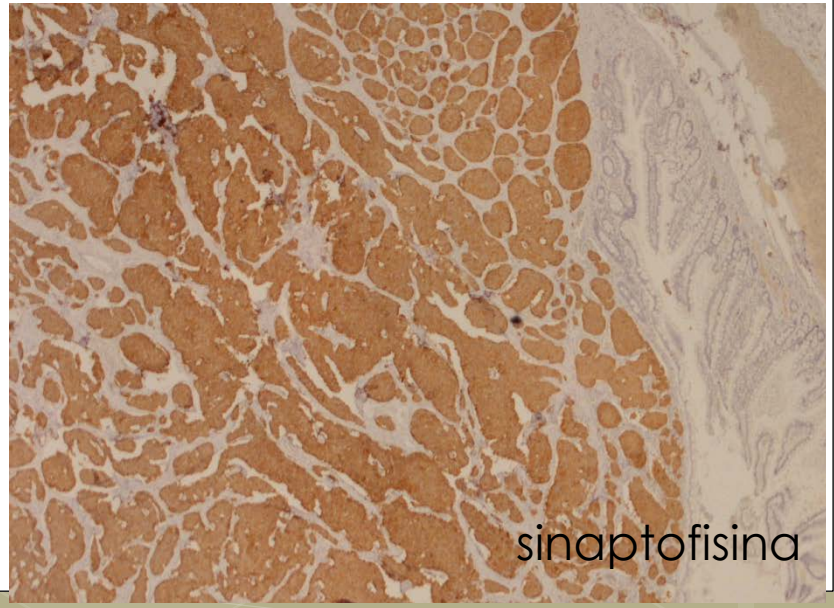

Post-operatorio

- Complicato da raccolta sottodiaframmatica sulla trancia di resezione epatica
- Evacuata con drenaggio percutaneo
- Terapia antibiotica

- TC addome
  - Al II segmento epatico: formazione ipodensa di 2,8 cm di diametro massimo

07/11/2012: 1° visita presso ns Centro

Paziente asintomatico

In terapia con Octreotide sc 0.1 mg x 3/die

Cromogranina **63.6** U/L (2.0 – 18)

Ac 5 OH IAA ur: 6.7 mg/die (0.7 – 8.2)

HbA1c: **41** mmol/mol

ECOCARDIOGRAFIA TRANSTORACICA: FE 73%; Insufficienza mitralica e aortica lieve-moderata; aneurisma setto interatriale; lieve dilatazione aorta ascendente; non alterazioni delle sezioni di destra

68-Ga-PET-Dotanoc/TC (Dicembre 2012)area di patologico accumulo al II° segmento epatico

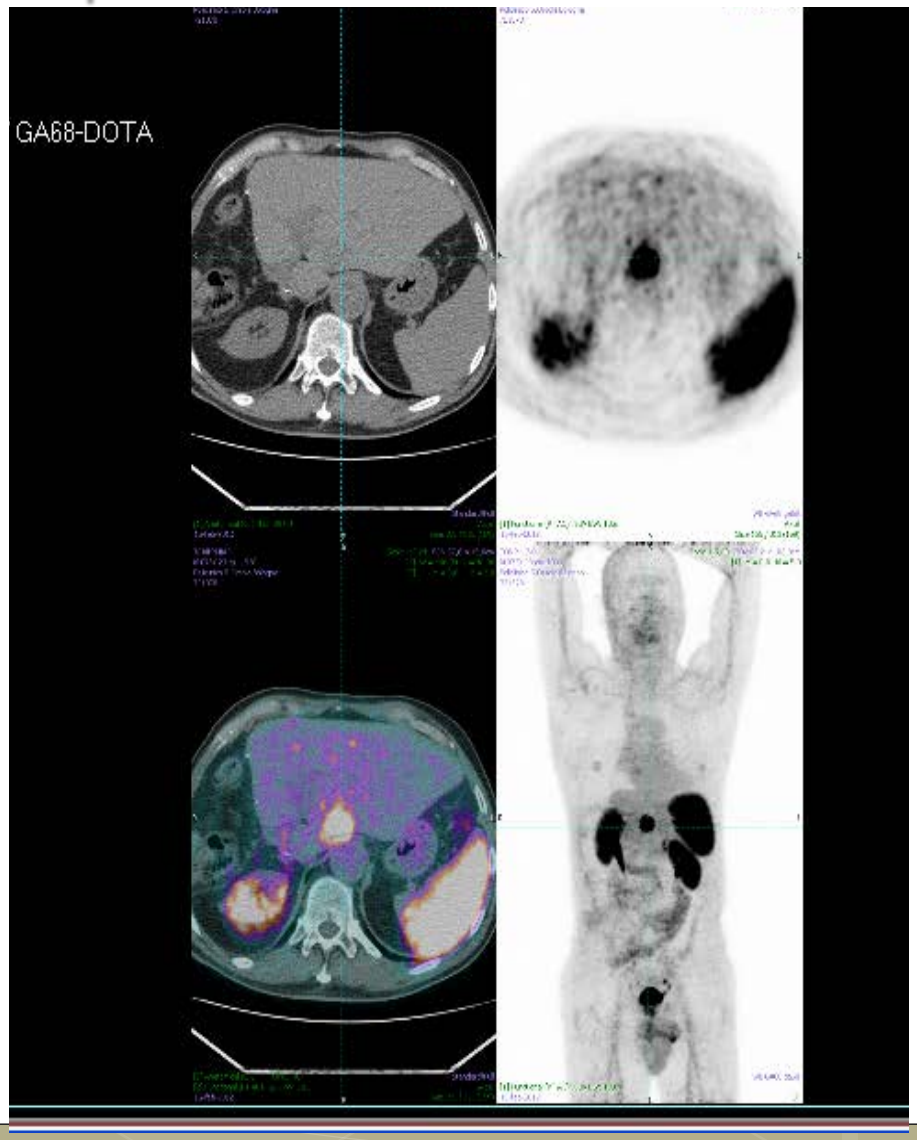

Imaging funzionale con analoghi SMS: quali le indicazioni cliniche?

- Individuazione tumore primitivo
- Stadiazione
- Ri-stadiazione
- Valutazione dello stato recettoriale SMS
- Monitoraggio della risposta a terapia
- Selezione dei pazienti eligibili per terapia radiorecettoriale



Avreste effettuato 18F-FDG-PET/TC?

GEP-NET: quando effettuare anche 18F-FDG-PET?

- Captazione di FDG: significativamente più elevata nei tumori ad alto grado
- 18F-FDG-PET/CT proposta nei GEP-NEN avanzati, metastatici
- L'associazione delle due tecniche di imaging funzionale può essere utile nella valutazione dei tumori di grado intermedio o elevato
- 18F-FDG-PET: elevata sensibilità nella stadiazione dei GEP-NENs con Ki67≥10-15%
- Forme FDG positive: prognosi peggiore

Predictive Value of ^{18}F-FDG PET and Somatostatin Receptor Scintigraphy in Patients with Metastatic Endocrine Tumors

Etienne Garin[1,2], Florence Le Jeune[1], Anne Devillers[1], Marc Cuggia[3], Anne-Sophie de Lajarte-Thirouard[4], Catherine Bouriel[1], Eveline Boucher[5], and Jean-Luc Raoul[2,5]

[1]UPRESS EA 3890 and Department of Medical Imaging, Centre E. Marquis, Rennes, France; [2]European University in Brittany, Brittany, France; [3]Department of Biostatistics, CHRU Pontchaillou, Rennes, France; [4]Department of Pathology, CHRU Pontchaillou, Rennes, France; and [5]Department of Medical Oncology, Centre E. Marquis, Rennes, France

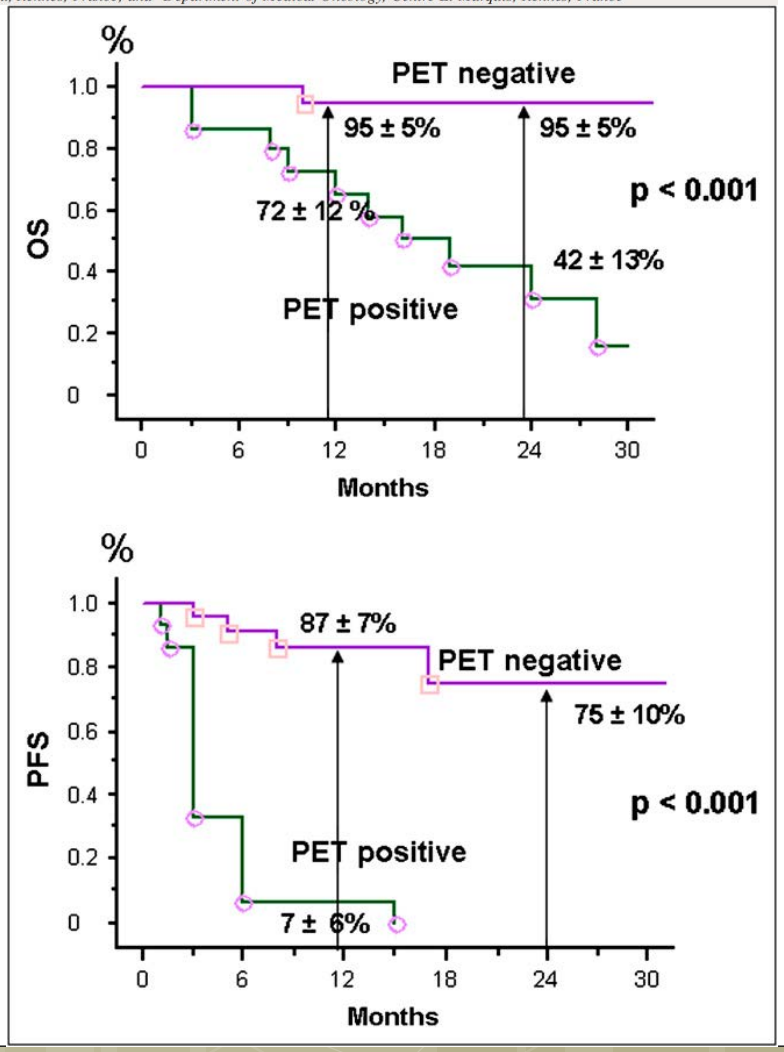

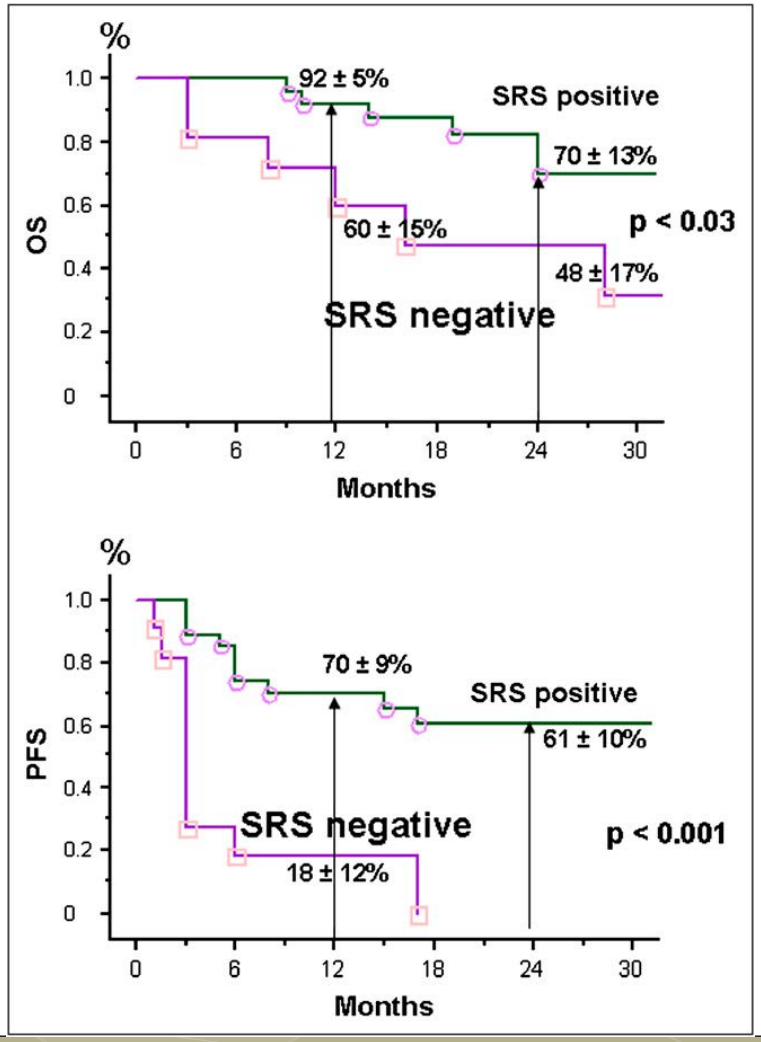

J Nucl Med 2009

ITALIAN ASSOCIATION OF CLINICAL ENDOCRINOLOGISTS (AME) POSITION STATEMENT
A STEPWISE APPROACH TO THE DIAGNOSIS OF GASTROENTEROPANCREATIC NEUROENDOCRINE TUMORS IN CLINICAL PRACTICE

Franco Grimaldi[1]*, Nicola Fazio[2]*, Roberto Attanasio[3], Andrea Frasoldati[4], Enrico Papini[5], Francesco Angelini[6], Roberto Baldelli[7], Debora Berretti[8], Sara Bianchetti[6], Giancarlo Bizzarri[9], Marco Caputo[10], Roberto Castello[11], Nadia Cremonini[12], Anna Crescenzi[13], Maria Vittoria Davì[14], Angela Valentina D'Elia[15], Antongiulio Faggiano[16], Stefano Pizzolitto[17], Annibale Versari[18], Michele Zini[4], on behalf of AME oncologic endocrinology group (other members of the group are listed after the text)
* FG and NF contributed equally as first authors

We recommend SSTR functional imaging as an established tool for diagnosis and staging of G1-G2 GEP-NETs.

We recommend PET/CT with 68Ga-labeled SA as the procedure of choice. When not available, 111In-pentetreotide (Octreoscan®) scintigraphy should be used.

We recommend against the routine use of 18F-FDG PET/CT.
We suggest 18F-FDG PET/CT for staging high grade (G3) and in selected G2 GEP-NETs.

Ritorniamo al signor Lino

US epatica mdc:

al II segmento sotto-capsulare, posteriormente al ramo portale segmentario corrispondente, lesione a bersaglio solida, di 3 cm, scarsi segnali vascolari,

ipervascolare dopo mdc in fase arteriosa

ipovascolare in fase portale



Come trattiamo il signor Lino?

- Iniziamo terapia con analoghi long acting della somatostatina?
- Valutiamo con il chirurgo l'exeresi della lesione epatica?
- Trattiamo la lesione epatica con terapia ablativa loco-regionale con radiofrequenza?
- Consideriamo terapia radiorecettoriale ?
- Altre terapie?

Octreotide and Lanreotide Improves Symptoms associated with Functioning GEP-NETs

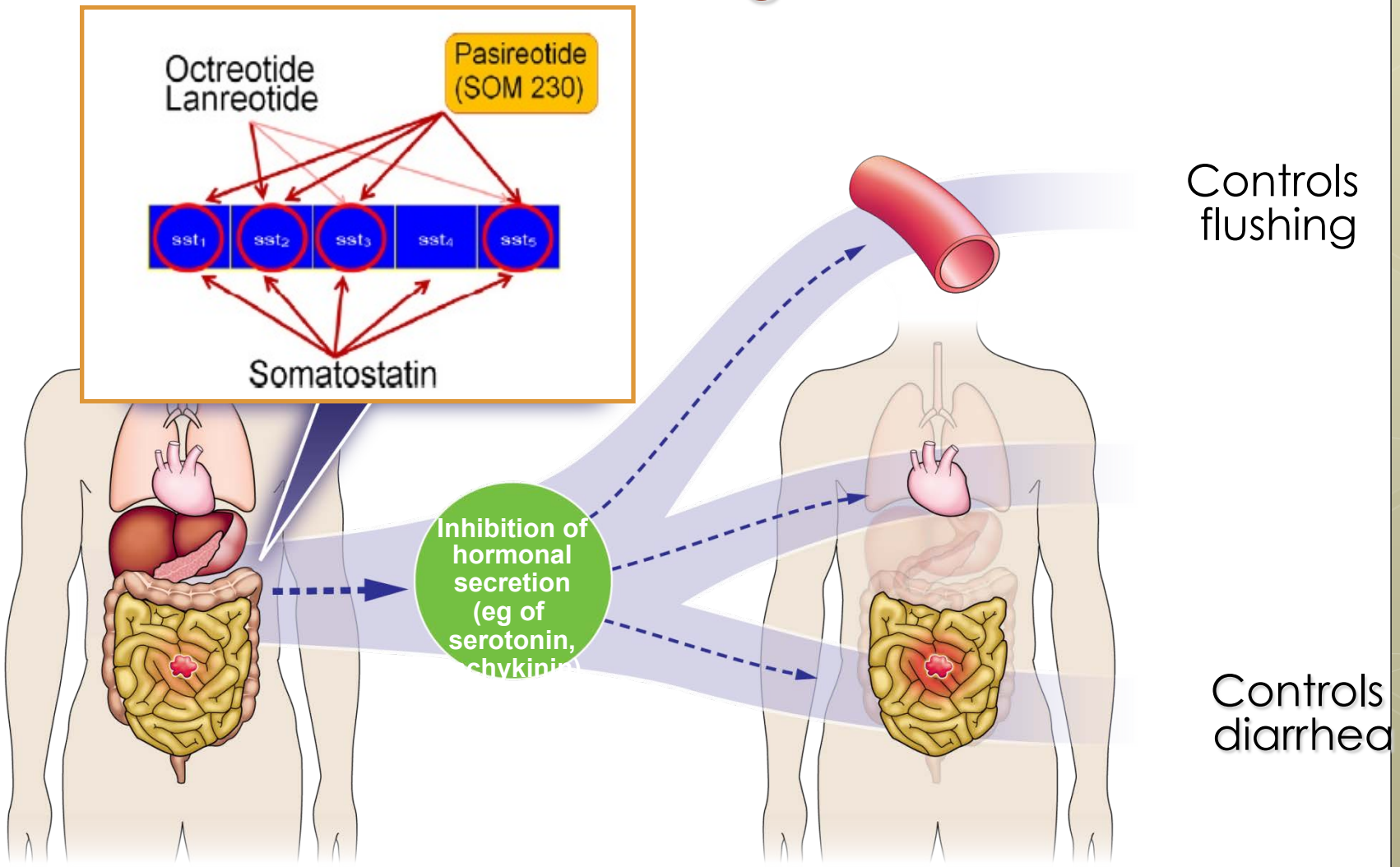

VOLUME 27 · NUMBER 28 · OCTOBER 1 2009

JOURNAL OF CLINICAL ONCOLOGY

ORIGINAL REPORT

Placebo-Controlled, Double-Blind, Prospective, Randomized Study on the Effect of Octreotide LAR in the Control of Tumor Growth in Patients With Metastatic Neuroendocrine Midgut Tumors: A Report From the PROMID Study Group

Anja Rinke, Hans-Helge Müller, Carmen Schade-Brittinger, Klaus-Jochen Klose, Peter Barth, Matthias Wied, Christina Mayer, Behnaz Aminossadati, Ulrich-Frank Pape, Michael Blaker, Jan Harder, Christian Arnold, Thomas Gress, and Rudolf Arnold



Table 3. Prognostic Factors for Time to Progression or Tumor-Related Death Adjusted for Treatment Based on the Per-Protocol Analysis

	Bivariate Analysis			Multivariate Analysis		
Factor	*P*	HR	95% CI	*P*	HR	95% CI
Octreotide LAR *v* placebo*				< .0001	0.27	0.14 to 0.49
Functional active tumor *v* inactive tumor	.2420	1.38	0.81 to 2.37			
Liver involvement > *v* ≤ 10%	.0009	2.81	1.53 to 5.18	.0023	2.63	1.41 to 4.90
Chromogranin A elevated *v* not elevated	.3098	1.36	0.75 to 2.48			
Karnofsky performance status ≤ *v* > 80%	.6518	1.21	0.54 to 2.71			
Age ≥ *v* < 63 years	.1709	1.47	0.85 to 2.56			
Primary tumor not resected *v* resected	.1040	1.60	0.91 to 2.80	.6784	1.45	0.60 to 2.20
Time since diagnosis ≥ *v* < 4.3 months	.0806	0.62	0.36 to 1.06	.2883	0.71	0.38 to 1.34

Abbreviation: HR, hazard ratio.
**P* value and effect size are only presented for multivariate analysis.

- Non opzioni terapeutiche curative.

No. of patients at risk

Placebo	43	41	39	29	27	25	19	14	11	8	6	4	2	0
Octreotide LAR	42	39	32	31	29	27	20	16	16	10	9	7	2	0

Log-rank test stratified by functional activity: $P = .77$, HR = 0.81 (95% CI, 0.30 to 2.18)

Fig 2. (A) Conservative intent-to-treat analysis of time to progression or tumor-related death. (B) Intent-to-treat analysis of overall survival. HR, hazard ratio.

A randomized double-blind placebo-Controlled study of Lanreotide Antiproliferative Response In patients with enteropancreatic NeuroEndocrine Tumours (CLARINET)

Martyn Caplin,[1] Philippe Ruszniewski,[2] Marianne Pavel,[3] Jarosław B Ćwikła,[4] Alexandria Phan,[5] Markus Raderer,[6] Eva Sedláčková,[7] Guillaume Cadiot,[8] Lucy Wall,[9] Guido Rindi,[10] Nilani Liyanage,[11] Joëlle Blumberg,[11] on behalf of the UK & Ireland Neuroendocrine Tumour Society, the European Neuroendocrine Tumor Society, and CLARINET Investigators

[1]Royal Free Hospital, London, UK; [2]Beaujon Hospital, Clichy, France; [3]Charité University Medicine Berlin, Germany; [4]Faculty of Medical Science, University of Warmia and Masuria, Olsztyn, Poland; [5]The Methodist Hospital, Houston, TX, USA; [6]University Hospital, Vienna, Austria; [7]General Faculty Hospital, Prague, Czech Republic; [8]Robert-Debré Hospital, Reims, France; [9]Western General Hospital, Edinburgh, UK; [10]Università Cattolica del Sacro Cuore, Rome, Italy; [11]Ipsen, Les Ulis, France

Presentation Presidential Session of the 17th ECCO – 38th ESMO – 32nd ESTRO European Cancer Congress, 28 September 2013, abstract E17-7103 , Amsterdam- EJC, vol 49 (3), 2013

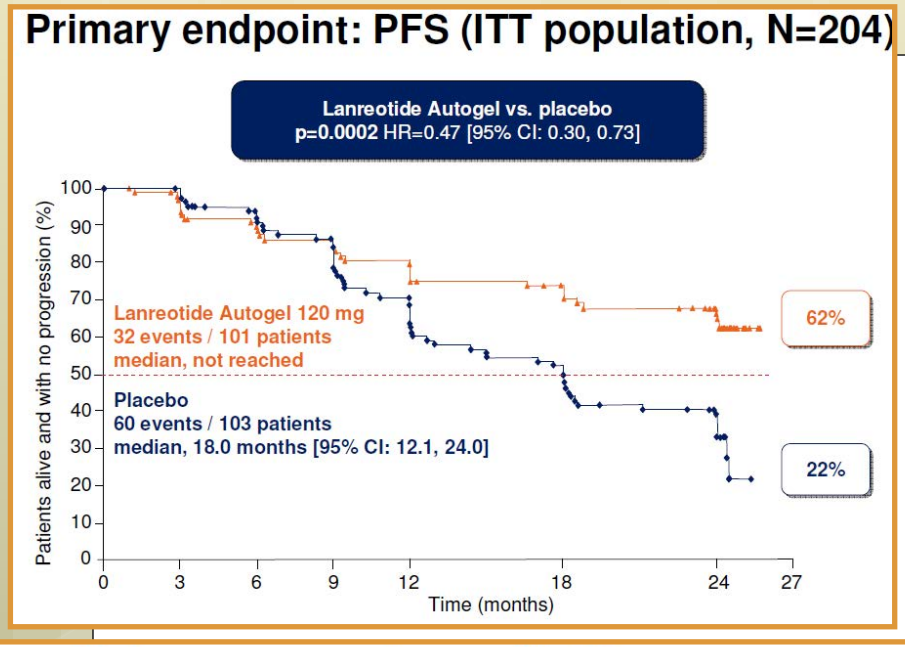

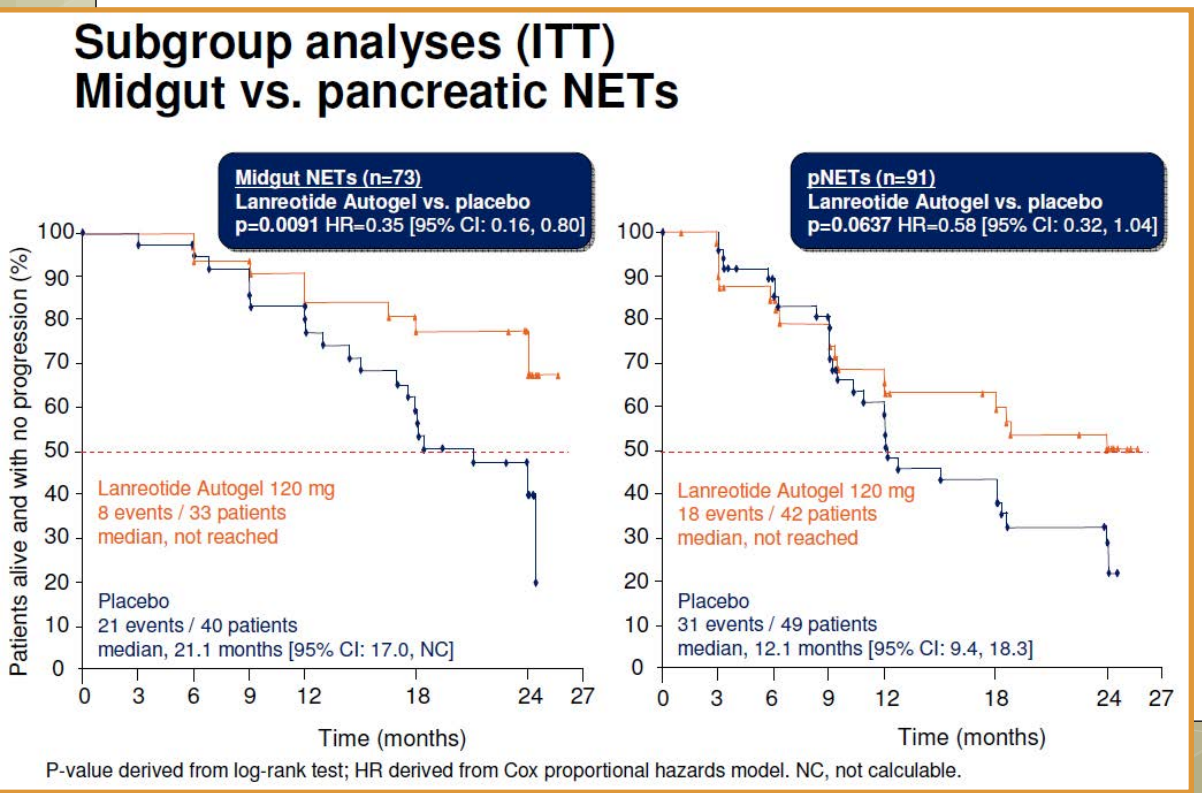

- 204 Pt
- GEP-NET bene o moderatamente differenziati
- Ki 67 <10%
- Tumori avanzati o M1 inoperabili
- Tumore misurabile sec RECIST
- Octreoscan: grado≥2
- Non terapie nei 6 mesi precedenti: INF, CHT, chemioembolizzazione

Effetto antiprolif. Riduzione del 53% del Rischio di progressione/ decesso

Caplin M et al. 2013

Subgroup analyses (ITT)
Effect of tumour grade

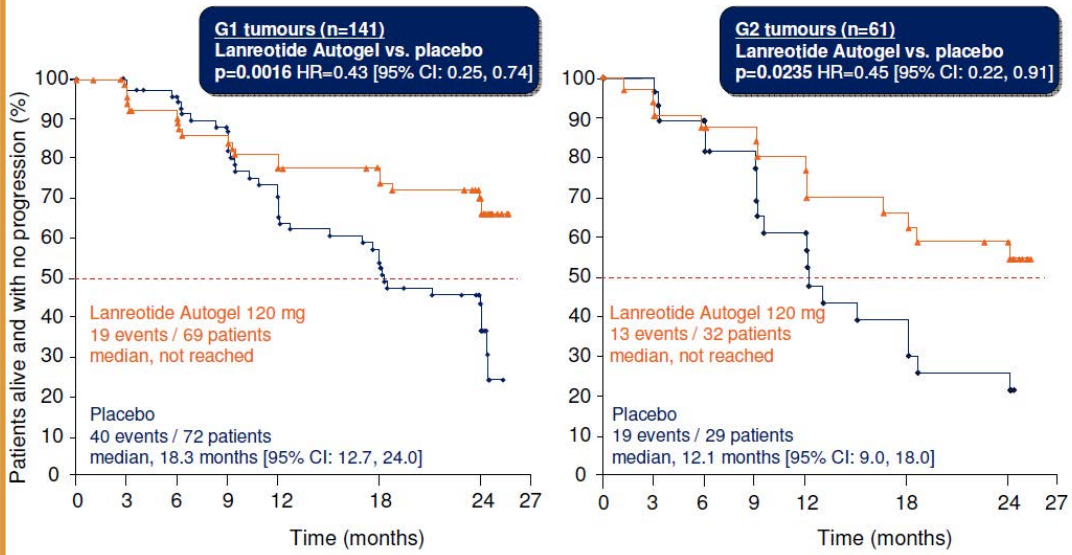

P-value derived from log-rank test; HR derived from Cox proportional hazards model.

Subgroup analyses (ITT)
Effect of hepatic tumour load

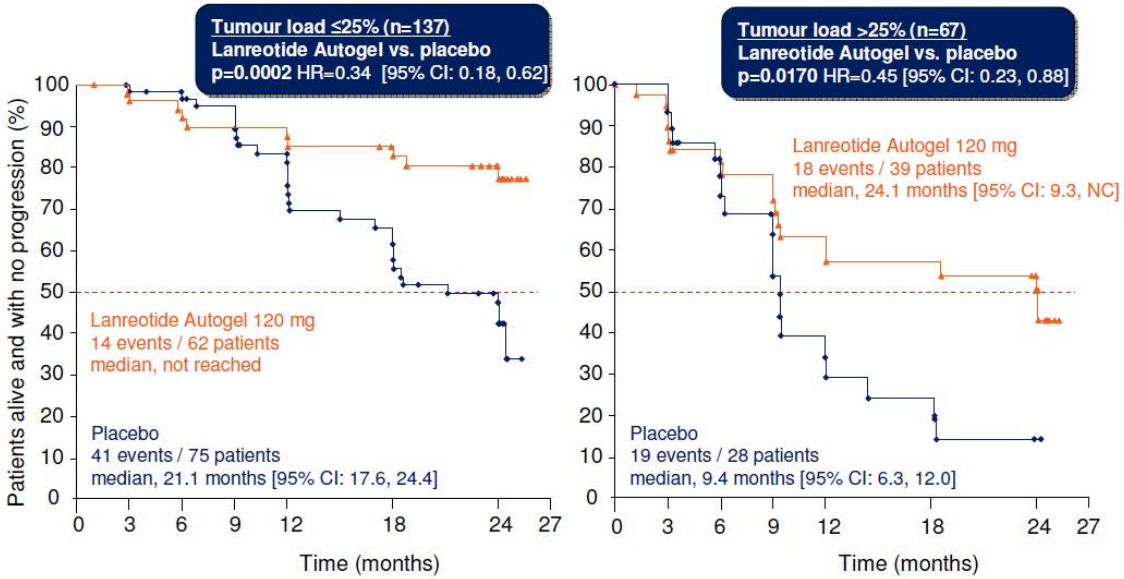

P-value derived from log-rank test; HR derived from Cox proportional hazards model. NC, not calculable.

Caplin M et al. 2013

Overall survival (ITT)

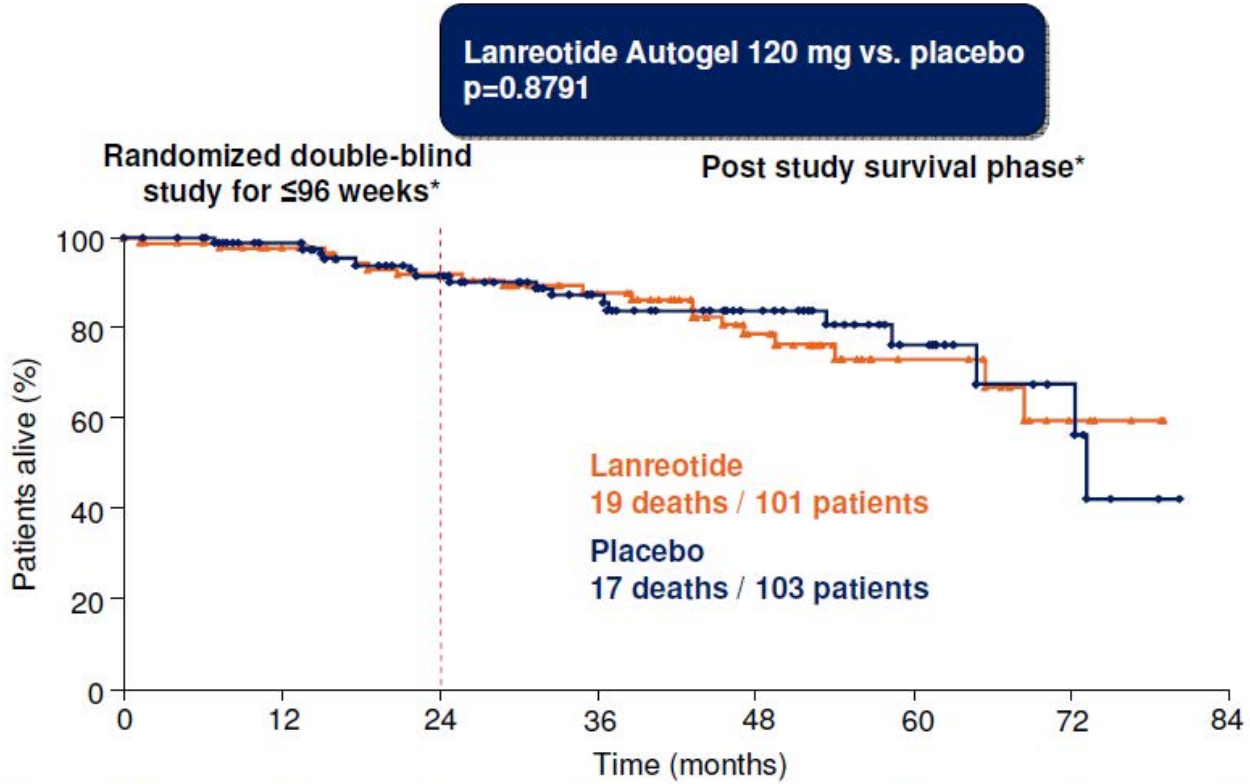

Lanreotide, n	101	89	78	59	37	14	5	0
Placebo, n	103	88	73	51	35	16	6	0

Non differenze in merito a sopravvivenza complessiva

Caplin M et al. 2013

Cosa ci dicono le Linee Guida? ESMO 2012

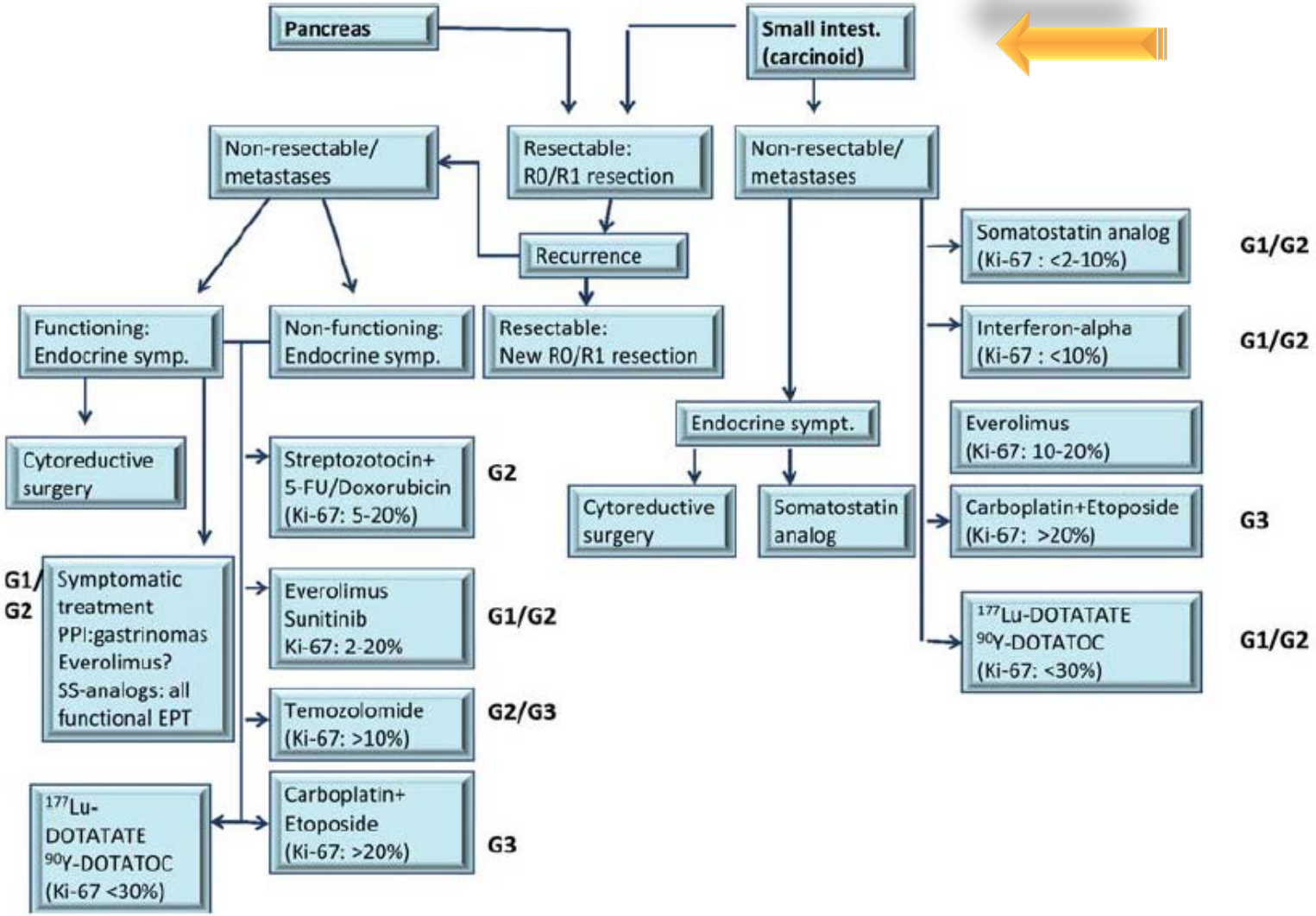

Oberg K et al. Ann Oncol 2012

Cosa ci dicono le Linee Guida? NCCN Guidelines 2014 version 1.2014 Carcinoid tumors

- Octreotide

  e
- Considerare terapia loco-regionale per M1 epatiche (embolizzazione arteriosa, chemioembolizzazione, radioembolizzazione (Categoria **2B**)

  oppure
- Considerare terapia chirurgica/ablativa citoriduttiva (Cat. **2B**)

  oppure
- Considerare Everolimus 10 mg/die (Categoria **3**)

  oppure
- Considerare chemioterapia, se non possibili altre opzioni (categoria **3**)

NET ileali - Terapia

- Opzioni terapeutiche ed evidenze limitate
- La strategia terapeutica deve essere basata su caratteri clinici/biologici del paziente e della neoplasia e decisa dal team multidisciplinare, e finalizzata agli obiettivi del trattamento